

Review

Inner Ear Disorders in SCUBA Divers: A Review

Alfonso Scarpa¹, Massimo Ralli², Pietro De Luca¹, Federico Maria Gioacchini³,
Matteo Cavaliere⁴, Massimo Re³, Ettore Cassandro¹, Claudia Cassandro⁵

¹Department of Medicine and Surgery, University of Salerno, Salerno, Italy

²Department of Sense Organs, Sapienza University of Rome, Rome, Italy

³Department of Molecular and Clinical Sciences, Università Politecnica delle Marche, Ancona, Italy

⁴Department of Otorhinolaryngology, University Hospital 'San Giovanni di Dio e Ruggi d'Aragona', Salerno, Italy

⁵Department of Surgical Sciences, University of Turin, Turin, Italy

ORCID IDs of the authors: A.S. 0000-0001-9219-6175; M.R. 0000-0001-8776-0421; P.L. 0000-0002-6505-1680; F.M.G. 0000-0002-1148-4384; M.C. 0000-0002-4071-6965; M.R. 0000-0002-0919-2155; E.C. 0000-0003-1757-6543; C.C. 0000-0003-4179-9181.

Cite this article as: Scarpa A, Ralli M, De Luca P, et al. Inner ear disorders in scuba divers: a review. *J Int Adv Otol.* 2021;17(3):260-264.

Self-Contained Underwater Breathing Apparatus (SCUBA) diving is a popular sport. However, improper diving may injure different organs. The majority of dive-related disorders concern otolaryngology, and may include hearing loss, tinnitus, aural fullness, disequilibrium, and vertigo. Three main inner ear pathological conditions can occur underwater: inner ear barotrauma (IEB), inner ear decompression sickness (IEDS), and alternobaric vertigo (AV). IEB results from inappropriate equalization of middle ear pressure and consequent inner ear injury produced by pressure changes within the middle ear; IEDS is characterized by the formation of gas bubbles within the vessels of the inner ear during rapid ascent; AV typically develops while ascending or performing the Valsalva maneuver and can follow asymmetrical equalization of middle ear pressure transmitted via the oval and round window membranes. The clinical pictures of these pathological conditions are partly superimposable, even if they have specific peculiarities. Before starting SCUBA diving, a fit-to-dive assessment is recommended. It should include an otolaryngologic examination with audiological assessment to evaluate nasal, middle ear, and tubal patency and to minimize the risk of IEB, IEDS, and AV. It is of utmost importance to identify individual risk factors and predisposing pathological conditions that favor inner ear injury before diving, to prevent acute events and preserve auditory and vestibular functions in SCUBA divers. This review aims to provide an overview of the pathological conditions characterized by inner ear injury in SCUBA divers, discussing their pathogenetic mechanisms, diagnostic work-up, and prevention.

KEYWORDS: Dizziness, vertigo, SCUBA diver

INTRODUCTION

There are millions of Self-Contained Underwater Breathing Apparatus (SCUBA) divers in the world, a popular activity appreciated at any age but not free from risks.^{1,2}

Nearly 80% of diving-related problems concern otolaryngology, and the ear is the most frequently involved organ.^{3,4} Among ear injuries, middle ear barotrauma is the most common condition,⁵ fortunately, in most cases, it resolves spontaneously in a short time without serious complications.⁵ Inner ear involvement is less common but usually more serious, often resulting in permanent hearing loss, tinnitus, vertigo, and unsteadiness.⁵

Inner ear disorders in SCUBA divers depend on 4 gas laws: Boyle's law (Figure 1), Henry's law (Figure 2), Charles's law, and Dalton's law.¹ Boyle's law states that at a constant temperature, there is an inverse relationship between the volume of a gas and its pressure. Henry's law states that the amount of dissolved gas in a liquid is proportional to its partial pressure above the liquid at a constant temperature. Charles's law states that a volume of gas equals a constant value multiplied by its temperature as measured on the Kelvin scale. Dalton's law states that the total pressure exerted is equal to the sum of the partial pressures of the individual gases.¹

There are 3 pathological conditions governed by gas laws that can affect the inner ear in SCUBA divers: Inner Ear Barotrauma (IEB), Inner Ear Decompression Sickness (IEDS), and Alternobaric Vertigo (AV). This review aims to provide a comprehensive overview of the different pathological conditions characterized by inner ear injury in SCUBA divers, discussing their pathogenetic mechanisms, diagnostic work-up, and prevention.

Corresponding author: Alfonso Scarpa, e-mail: alfonsoскарпа@yahoo.it

Received: June 1, 2020 • **Accepted:** November 9, 2020

Available online at www.advancedotology.org



Content of this journal is licensed under a
Creative Commons Attribution-NonCommercial
4.0 International License.

Boyle's Law

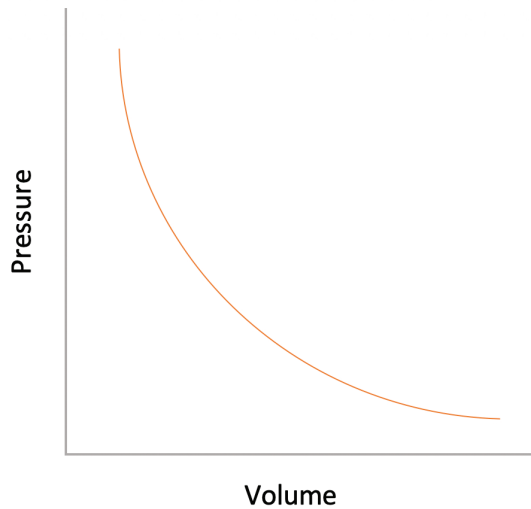


Figure 1. Boyle's law: at a given temperature, the volume of a gas is inversely proportional to its pressure.

CLINICAL AND RESEARCH CONSEQUENCES

Inner Ear Barotrauma (IEB)

IEB results from inappropriate equalization of middle ear pressure and consequent injury produced by pressure changes within the middle ear transmitted to the cochlea through the round and/or oval window.⁶ The round window is most commonly affected because it is covered by a thin membrane, whereas the oval window maintains greater stability thanks to the stapes footplate, stapedial muscle, and associated ligaments.⁷ Two pathological conditions may favor inner ear damage during descent: one with normal Eustachian tube function, the other when the tube is obstructed (Figure 3).⁷ In the first case, vigorous Valsalva maneuver may cause an uncontrolled increase in middle ear pressure with a violent outward displacement of the stapes footplate and inward movement of the slight round window membrane. In the second case, the blocked Eustachian tube does not allow middle ear pressure equalization and consequently

Schematics of Inner Ear Barotrauma

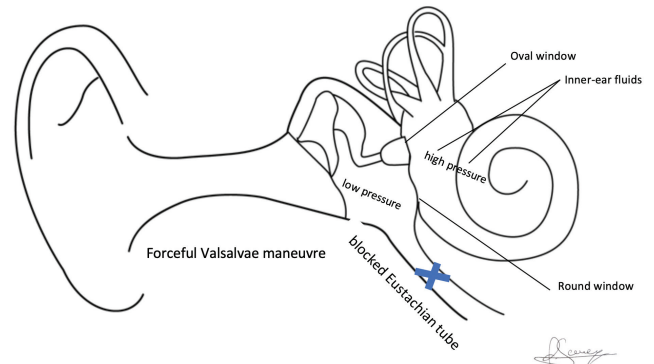


Figure 3. Schematic diagram of inner ear barotrauma: pressure increases during descent and a Valsalva maneuver can help equalize the middle ear pressure. (A) In the case of a patent Eustachian tube, if a vigorous Valsalva maneuver is performed, an uncontrolled increase in pressure in the middle ear occurs with a consequently violent outward displacement of the stapes footplate and inward movement of the slight round window membrane. (B) If the Eustachian tube is blocked, lower pressure in the middle ear occurs. A forceful Valsalva at this stage can increase the cerebrospinal fluid pressure (CFP) and consequently favor round or oval window rupture.

generates a pressure difference between the middle ear, the external ear canal, and the inner ear fluids. A forceful Valsalva at this stage can increase the cerebrospinal fluid pressure (CFP), and consequently the pressure in the inner ear, causing rupture of the round or oval window.^{8,9} There are many pathogenetic mechanisms that explain inner ear injury due to IEB: hemorrhage following rupture of blood vessels in the cochlea, a tear in the Reissner's membrane or in the basilar membrane, perilymph fistula, and pneumolabyrinth.¹⁰⁻¹²

There are some anatomic risk factors that can predispose to IEB: an enlarged cochlear aqueduct orifice that may quickly increase CFP;¹³ and a shorter cochlear aqueduct, typically among pediatric divers, inducing IEB due to pressure fluctuations within the subarachnoid space.¹⁴

Clinical signs and symptoms of IEB include sudden sensorineural hearing loss (SNHL), sometimes accompanied by aural fullness, tinnitus, and hyperacusis,¹³ and vestibular symptoms such as persistent or recurrent vertigo, nystagmus, dizziness, and disequilibrium. In about 40% of the cases, SNHL is typically the only presenting complaint in isolated basilar membrane tears.¹⁵ In about 10% of cases, vestibular symptoms are the only sign of IEB. Otoscopic findings like congestion, retraction, hematoma, and eardrum perforation related to middle ear barotrauma are often found in patients with IEB.

Before initiation of therapy, clinicians should exclude an IEDS by investigating the dive profile and the mixture of gases used and perform an otoscopic and neurologic examination, pure-tone audiometry, a fistula test, and electronystagmography (ENG).¹⁶⁻¹⁹ Furthermore, patients should be positioned with the head elevated, and pressure-elevating maneuvers should be prevented. A consensus on therapy does not exist, but high doses of steroids for 15-20 days are recommended as the first line of therapy, based on expert opinion.²⁰ Early surgical exploration is advised when a perilymphatic fistula is suspected.²¹

Henry's Law

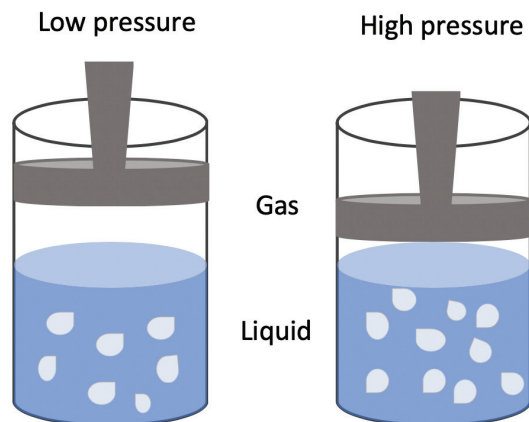


Figure 2. Henry's law: at a constant temperature, the amount of dissolved gas in a liquid is proportional to its partial pressure above the liquid.

Inner Ear Decompression Sickness (IEDS)

IEDS is a phenomenon characterized by the formation of gas bubbles within the vessels of the inner ear during rapid ascent that causes an abrupt reduction in ambient pressure.²² The vestibular portion of the inner ear is the most affected because it has higher tissue volume and smaller blood supply and thus a slow washout period.^{23,24} All this promotes supersaturation of the vestibular apparatus and consequently vascular bubble overload.¹⁷ Although the exact pathogenetic mechanism is still unclear; it has been speculated that gas bubbles can interact with the endothelium of blood vessels in the labyrinth and trigger an inflammatory reaction with the activation of the coagulation cascade and subsequent hypoxic injury can occur.^{16,25} Another plausible hypothesis is the direct damage of membranous labyrinth and local microvessels by the formation of microbubbles in the endolymphatic and perilymphatic spaces.²⁶ Yet another theory is that of arterial gas emboli traveling from venous circulation through a right-to-left cardiac shunt (RLS) and subsequent occlusion of the labyrinthine artery. RLS is often present in patent foramen ovale (PFO), is relatively common, and is seen in up to 25% of the general population and nearly 50% of SNHL cases.^{18,24,27–32} The risk factors are old age, female gender, alcohol consumption, overweight, and obesity.

Vestibular symptoms are more frequent than cochlear ones (such as hearing loss), occur within 2 hours after the dive, and include vertigo, dizziness, nausea, and vomiting. The diagnosis of IEDS is superimposable to IEB (Table 1). The neurological investigation should be performed, as it has prognostic value.^{16–19}

Treatment requires immediate supplemental oxygen and recompression.^{19,20}

Alternobaric Vertigo (AV)

AV is a condition characterized by transient vertigo that typically develops while ascending or performing the Valsalva maneuver.^{33,34} AV can follow asymmetrical equalization of middle ear pressure transmitted via the oval and round window membranes. Women are more frequently affected than males, although reasons are still unclear.³⁵

Risk factors for AV include noise exposure during diving, cold-water diving, previous barotrauma, recurrent otitis media, female gender, unilaterally blocked Eustachian tube or function, and difficulty in clearing ears during diving.^{33,36–38}

AV's clinical features include transient vertigo that lasts from seconds to minutes, typically accompanied by nausea and sporadically by vomiting.^{33,37,38} The typical triad is transient vertigo, no auditory symptoms, and difficulty equalizing middle ear pressure.^{33,34}

When dizziness occurs underwater, it is appropriate to ascend slowly, using the Frenzel technique, or alternatively, the Toynbee maneuver; if unsuccessful, descend to perform the Valsalva maneuver. In fact, decreased visibility and buoyancy underwater result in impaired visual and proprioceptive cues, consequently increasing the reliance on vestibular information. Therefore, if a vestibular disorder occurs underwater, it could pose an increased risk to the diver's safety.^{37,39} Divers should learn how to handle vomiting underwater before diving.

Recommendations to Reduce the Risk of Inner Ear Injury

Before starting SCUBA diving, a fit-to-dive assessment is recommended to exclude physical conditions contraindicated in this activity. Particularly, an otolaryngologic examination with audiological assessment should be performed to evaluate nasal, middle ear, and tubal patency and function to minimize the risk of IEB, IEDS, and AV.¹⁹ A careful inspection of the nasal cavity and of the nasopharyngeal orifice of Eustachian tubes is highly recommended to identify causes of nasal obstruction like allergic rhinitis, deviated septum, turbinate hypertrophy, and nasal polyps. Furthermore, an otomicroscopy and pneumatic otoscopy are recommended to better visualize external the auditory canal and tympanic membrane at rest and when moving in response to pressure. Audiological assessment should include pure-tone audiometry, tympanometry, and Eustachian tube function tests.^{5,18–20,40,41} Tubal function tests can be affected by many factors and may not always show exact function. However, size of mastoid aeration can be related to the long-term ability of the Eustachian tube function. Thus, measuring the degree of mastoid pneumatization can also be used to indirectly evaluate pressure equalization potential.^{42,43} Moreover, in selected patients, a

Table 1. Clinical Features and Therapeutic Approach to Middle and Inner Ear Conditions Occurring During a Dive

	Inner Ear Barotrauma	Alternobaric Vertigo	Inner Ear Decompression Sickness
Involved organs	Cochlea and vestibule	Cochlea	Vestibule
Diving stage	During ascent or descent	During ascent	During ascent and deep diving
Onset of symptoms	During diving	During diving	Symptom-free interval after diving
Middle ear involvement	Often	Absent	Absent
Hearing alterations	Sensorineural or mixed hearing loss; aural fullness; tinnitus; hyperacusis	Absent	Sensorineural hearing loss; aural fullness; tinnitus
Vestibular alterations	Dizziness or vertigo; Nystagmus toward the healthy side; Canal paresis (caloric test); Head impulse test toward the affected side	Transient vertigo; Transient nystagmus beating toward the pressurized ear; Normal caloric and head impulse test	Dizziness or vertigo; Nystagmus toward the healthy side; Canal paresis (caloric test); Head impulse test toward the affected side
Therapy	High dose steroids for 15–20 days; Surgical exploration if fistula is suspected	No therapy; Toynbee maneuver during ascent; Valsalva maneuver during descent	Supplemental oxygen and recompression

cardiovascular examination with an echocardiogram and transcranial doppler ultrasound should be performed to identify a PFO and to rule out an RLS.^{24,29-31}

During diving, middle ear equalization using the Valsalva, Toynbee, or Frenzel maneuvers should be performed to prevent IEB and AV. The Eustachian tube opens easier in the head- or ear-up position than in the head-down position. Therefore, divers who have difficulties opening their ears can be advised to dive feet-down.^{44,45}

Diving should be suspended whenever middle ear equalizations become difficult. In cases of recurrent attacks of dizziness and/or hearing alterations because of diving, an otoneurologic examination is recommended, including high-resolution computed tomography of the temporal bone to rule out anatomic risk factors such as widened cochlear aqueduct orifice and enlarged internal auditory canal.^{5,13,19,40}

In patients with Eustachian tube dysfunction, balloon tuboplasty may be helpful to prevent equalization problems while diving, even though there is no clear evidence of success.^{13,46}

Diving should be suspended whenever middle ear equalizations become difficult, especially when a diver has an upper respiratory tract infection. It should also be suspended in patients undergoing some types of surgery, such as middle ear surgery, cochlear implantation, and sinus surgery, and the return to diving should follow strict recommendations.⁴⁰ Diving activity can resume 3 months after myringoplasty and tympanoplasty with or without insertion of a partial ossicular replacement prosthesis.⁴⁷ Some surgical techniques can be preferred in divers.⁴⁸ After stapes surgery, it is necessary to examine otoneurologic and tubal function before starting a diving activity, to evaluate the vestibular function and exclude a labyrinth irritation.^{47,49,50} However, all divers who undergo ossiculoplasty or stapedectomy must be warned of potential risks.

Patients with cochlear implants should be assessed before starting or resuming diving activities because risk of inner ear injury exists.⁵¹ After sinus surgery, it is a good practice to perform a test drive under supervision before certifying fitness to dive.¹⁷

CONCLUSION

SCUBA diving has become a progressively popular sport worldwide. Otolaryngologic disorders related to diving are common and sometimes extremely dangerous, especially when the inner ear is involved. Inner ear damage while diving constitutes a potentially life-threatening situation when occurring underwater because it may induce disorientation, anxiety, and panic. The identification of individual risk factors and predisposing pathological conditions that favor inner ear injury before diving is of utmost importance to prevent acute events and preserve auditory and vestibular functions in SCUBA divers.

Peer Review: Externally peer-reviewed.

Author Contributions: Concept – A.S., M.R., P.D.L., F.M., M.C., M.Re, E.C., C.C.; Design – A.S., M.R., P.D.L., F.M., M.C., M.Re, E.C., C.C.; Supervision – A.S., M.R., P.D.L., F.M., M.C., M.Re, E.C., C.C.; Literature Search – A.S., M.R., P.D.L., F.M., M.C.,

M.Re, E.C., C.C.; Writing – A.S., M.R., P.D.L., F.M., M.C., M.Re, E.C., C.C.; Critical Reviews – A.S., M.R., P.D.L., F.M., M.C., M.Re, E.C., C.C.

Conflict of Interest: The authors have no conflict of interest to declare.

Financial Disclosure: The authors declared that this study has received no financial support.

REFERENCES

1. Raymond KA, Cooper JS. *Scuba Diving*. Treasure Island (FL): StatPearls; 2020.
2. Abramovich A, Yanir Y, Shupak A. Medical problems in scuba diving. *Chest*. 2001;120(3):1040.
3. Roydhouse N. 1001 disorders of the ear, nose and sinuses in scuba divers. *Can J Appl Sport Sci*. 1985;10(2):99-103.
4. Strutz J. Otorhinolaryngologic aspects of diving sports. *HNO*. 1993;41(8):401-411.
5. Livingstone DM, Smith KA, Lange B. Scuba diving and otology: a systematic review with recommendations on diagnosis, treatment and post-operative care. *Diving Hyperb Med*. 2017;47(2):97-109.
6. Lechner M, Sutton L, Fishman JM, et al. Otorhinolaryngology and diving-part 1: otorhinolaryngological hazards related to compressed gas scuba diving: a review. *JAMA Otolaryngol Head Neck Surg*. 2018;144(3):252-258.
7. On OJ, Brett K, Frank AJ. *Ear Barotrauma*. Treasure Island (FL): StatPearls; 2020.
8. Azizi MH. Ear disorders in scuba divers. *Int J Occup Environ Med*. 2011;2(1):20-26.
9. Clenney TL, Lassen LF. Recreational scuba diving injuries. *Am Fam Physician*. 1996;53(5):1761-1774.
10. Glazer TA, Telian SA. Otologic hazards related to scuba diving. *Sports Health*. 2016;8(2):140-144.
11. Skogstad M, Eriksen T, Skare Ø. A twelve-year longitudinal study of hearing thresholds among professional divers. *Undersea Hyperb Med*. 2009;36(1):25-31.
12. Parell GJ, Becker GD. Inner ear barotrauma in scuba divers: a long-term follow-up after continued diving. *Arch Otolaryngol Head Neck Surg*. 1993;119(4):455-457.
13. Shupak A. Recurrent diving-related inner ear barotrauma. *Otol Neurotol*. 2006;27(8):1193-1196.
14. Marchese-Ragona R, Marioni G, Ottaviano G et al. Pediatric sudden sensorineural hearing loss after diving. *Auris Nasus Larynx*. 2007;34(3):361-364.
15. Love Jr JT, Waguespack RW. Perilymphatic fistulas. *Laryngoscope*. 1981;91(7):1118-1128.
16. Boyd KL, Wray AA. *Inner Ear Decompression Sickness (IEDCS)*. Treasure Island (FL): StatPearls; 2020.
17. Klingmann C. Inner ear decompression sickness in compressed-air diving. *Undersea Hyperb Med*. 2012;39(1):589-594.
18. Mitchell SJ. DCS or DCI? The difference and why it matters. *Diving Hyperb Med*. 2019;49(3):152-153.
19. Rozycki SW, Brown MJ, Camacho M. Inner ear barotrauma in divers: an evidence-based tool for evaluation and treatment. *Diving Hyperb Med*. 2018;48(3):186-193.
20. Klingmann C, Praetorius M, Baumann I, Plinkert PK. Barotrauma and decompression illness of the inner ear: 46 cases during treatment and follow-up. *Otol Neurotol*. 2007;28(4):447-454.
21. Morvan JB, Gempp E, Rivière D et al. Perilymphatic fistula after underwater diving: a series of 11 cases. *Diving Hyperb Med*. 2016;46(2):72-75.
22. Nachum Z, Shupak A, Spitzer O et al. Inner ear decompression sickness in sport compressed-air diving. *Laryngoscope*. 2001;111(5):851-856.
23. Guenzani S, Mereu D, Messersmith M et al. Inner-ear decompression sickness in nine trimix recreational divers. 2016;46(2):111-116 *Diving Hyperb Med*.

24. Mitchell SJ, Doolette DJ. Pathophysiology of inner ear decompression sickness: potential role of the persistent foramen ovale. *Diving Hyperb Med.* 2015;45(2):105-110.
25. Tremolizzo L, Malpieri M, Ferrarese C, Appollonio I. Inner-ear decompression sickness: 'hubble-bubble' without brain trouble? *Diving Hyperb Med.* 2015;45(2):135-136.
26. Money KE, Buckingham IP, Calder IM et al. Damage to the middle ear and the inner ear in underwater divers. *Undersea Biomed Res.* 1985;12(1):77-84.
27. Capuano L, Cavaliere M, Lopardo D et al. Right-to-left shunt and idiopathic sudden sensorineural hearing loss. *Acta Otorhinolaryngol Ital.* 2019;39(2):103-106.
28. Wilmshurst P. Risk mitigation in divers with persistent (patent) foramen ovale. *Diving Hyperb Med.* 2019;49(2):77-78.
29. Lafère P, Balestra C, Caers D, Germonpré P. Patent foramen ovale (PFO), personality traits, and iterative decompression sickness. Retrospective analysis of 209 cases. *Front Psychol.* 2017;8:1328.
30. Wilmshurst PT. The role of persistent foramen ovale and other shunts in decompression illness. *Diving Hyperb Med.* 2015;45(2):98-104.
31. Germonpré P. Persistent (patent) foramen ovale (PFO): implications for safe diving. *Diving Hyperb Med.* 2015;45(2):73-74.
32. Honěk J, Srámek M, Sefc L et al. Effect of conservative dive profiles on the occurrence of venous and arterial bubbles in divers with a patent foramen ovale: a pilot study. *Int J Cardiol.* 2014;176(3):1001-1002.
33. Francescon D, Cooper JS. *Alternobaric Vertigo*. Treasure Island (FL): StatPearls; 2020.
34. Kitajima N, Sugita-Kitajima A, Kitajima S. Altered Eustachian tube function in SCUBA divers with alternobaric vertigo. *Otol Neurotol.* 2014;35(5):850-856.
35. Klingmann C, Knauth M, Praetorius M, Plinkert PK. Alternobaric vertigo—really a hazard? *Otol Neurotol.* 2006;27(8):1120-1125.
36. Uzun C, Yagiz R, Tas A et al. Alternobaric vertigo in sport SCUBA divers and the risk factors. *J Laryngol Otol.* 2003;117(11):854-860.
37. Molvaer OI, Albrektsen G. Alternobaric vertigo in professional divers. *Undersea Biomed Res.* 1988;15(4):271-282.
38. Farmer JC, Jr. Diving injuries to the inner ear. *Ann Otol Rhinol Laryngol Suppl.* 1977;86(1 Pt 3 Suppl 36):1-20.
39. Molvaer OI. Vestibular problems in diving and in space. *Scand Audiol Suppl.* 1991;34:163-170.
40. Elliott EJ, Smart DR. The assessment and management of inner ear barotrauma in divers and recommendations for returning to diving. *Diving Hyperb Med.* 2014;44(4):208-222.
41. Uzun C, Adali MK, Tas A et al. Use of the nine-step inflation/deflation test as a predictor of middle ear barotrauma in sports scuba divers. *Br J Audiol.* 2000;34(3):153-163.
42. Uzun C, Adali MK, Kotev M et al. Relationship between mastoid pneumatization and middle ear barotrauma in divers. *Laryngoscope.* 2002;112(2):287-291.
43. Uzun C. Evaluation of pre-dive parameters related to Eustachian tube dysfunction for symptomatic middle ear barotrauma in divers. *Otol Neurotol.* 2005;26(1):59-64.
44. Ranapurwala SI, Poole C, Marshall SW et al. Factors influencing adherence to pre-dive checklists among recreational scuba divers. *Undersea Hyperb Med.* 2016;43(7):827-832.
45. Foster PP, Boriek AM, Butler BD, Gernhardt ML, Bové AA. Patent foramen ovale and paradoxical systemic embolism: a bibliographic review. *Aviat Space Environ Med.* 2003;74(6 Pt 2):B1-B64.
46. Ungar OJ, Cavel O, Yahav O, Tsur N, Handzel O. Outcome of balloon eustachian tuboplasty in SCUBA divers. *Ear Nose Throat J.* 2020;145561320933957.
47. Klingmann C, Wallner F. Tauchmedizinische Aspekte in der HNO-Heilkunde. 2.Teil: Tauchtauglichkeit [Health aspects of diving in ENT medicine. Part II: diving fitness]. *HNO.* 2004;52(9):845-847;58-59.
48. Velepich M, Bonifacic M, Manestar D, Velepich M, Bonifacic D. Cartilage palisade tympanoplasty and diving. *Otol Neurotol.* 2001;22(4):430-432.
49. House JW, Toh EH, Perez A. Diving after stapedectomy: clinical experience and recommendations. *Otolaryngol Head Neck Surg.* 2001;125(4):356-360.
50. Antonelli PJ, Adamczyk M, Appleton CM, Parell GJ. Inner ear barotrauma after stapedectomy in the guinea pig. *Laryngoscope.* 1999;109(12):1991-1995.
51. Hintze JM, Geyer L, Fitzgerald CW et al. The impact of repetitive hyperbaric exposure during SCUBA diving on cochlear implants. *Laryngoscope.* 2019;129(12):2760-2764.